

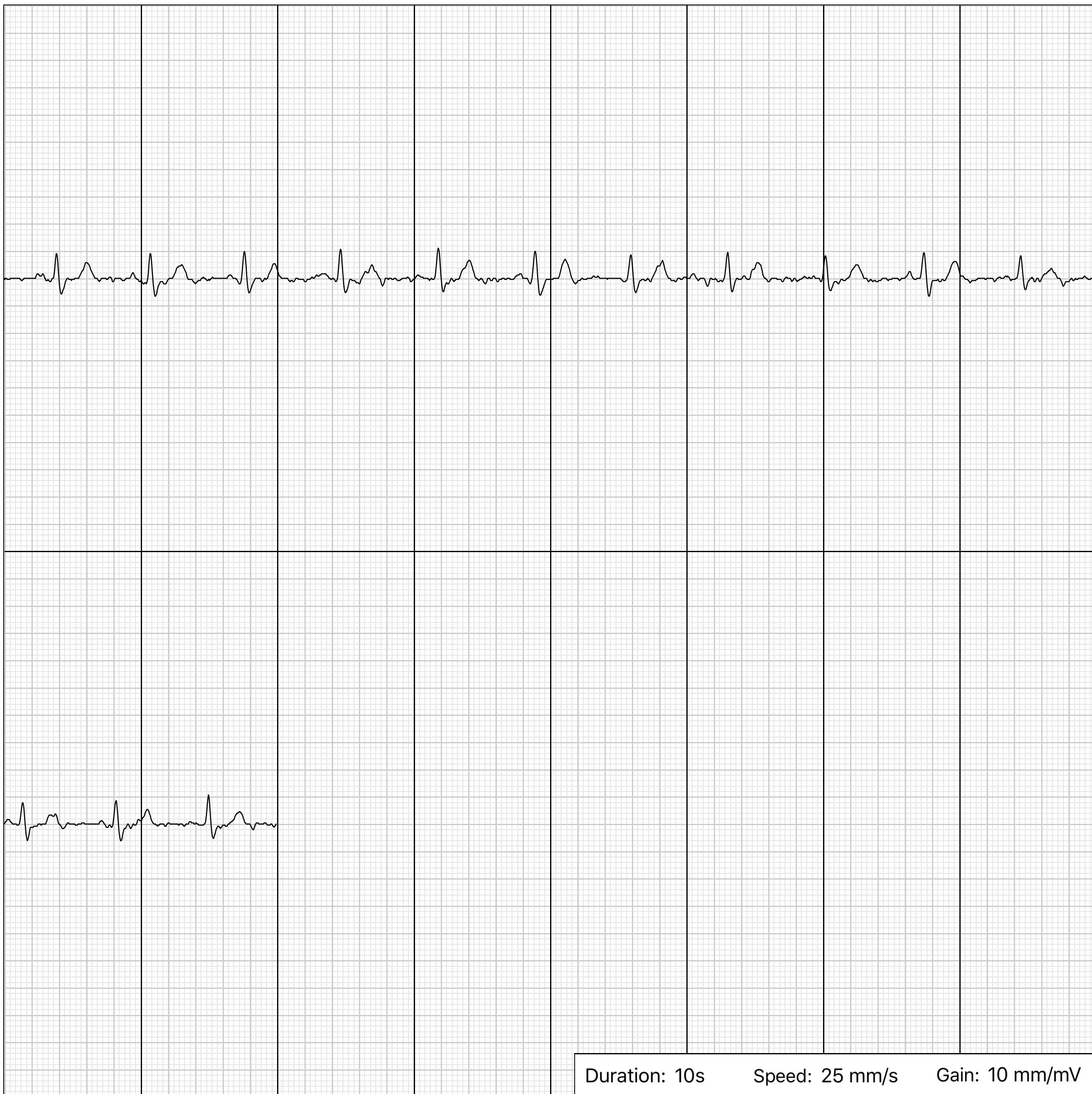
ECG Report

Patient: Dan

Tip: No Abnormalities

Recorded: 12/14/2018 12:18:18 PM

Heart Rate: 86 bpm



HR:86 bpm, No Abnormalities